



TANA FOUNDATION INDIA (TFI)

PROJECT VAARADHI - MEDICAL REFERRALS (2015-2017)



STUDENT DETAILS:

- **Name:** S. Uma Maheshwara rao
- **Contact:** 96425 77731
- **Age:** 15 Yrs.
- **Class:** 9th class
- **School:** ZPHS Geddanapalli, Kirlampudi Mandal



MEDICAL HISTORY: Heart Disease

MEDICAL CAMP REPORT (Aug -2015)

- **Doctor:** Dr. NARAYANA BABU (pediatrician), C/O Sai Sudha Hospital, Kakinada.
- **Complaint:** Chest pain, Failure to Thrive
- **Advised:** Cardiologist Opinion, Ophthalmologist opinion
- **Diagnosis:** Rheumatic heart disease
- **Treatment given:** 1.Tab.Erythromycin 250 mg BD (**LIFE LONG PROPHYLAXIS**)

REFERAL DOCTOR REPORT:

- **Doctor 1:** – Dr. Srinivas MD .DM Cardiologist, C/o Sai Sudha Hospital, Kakinada.
 - **Advised** –2D Echocardiography (TEST)
 - **Diagnosis**-Rheumatic heart disease
 - **Treatment Given:** -> No Surgery needed.
 - Tab.Erythromycin 250 mg BD (**LIFE LONG PROPHYLAXIS**)
- **Doctor 2:** Dr. Avinash, Ophthalmologist, C/o Sri Kiran Eye hospital, Kakinada.
 - **Complaint:** Sudden Blurring of vision.
 - **Diagnosis:** No problem
 - **Advised:** Regular follow-up
 - **Treatment Given** -- Nil

PRESENT CONDITION: He is Healthy now, and taking healthy diet to improve the general condition of the body. He has been supplied with protein powder for better nutrition levels.



TANA FOUNDATION INDIA (TFI)

PROJECT VAARADHI - MEDICAL REFERRALS (2015-2017)



STUDENT DETAILS:

- **Name:** Gorla Vijay
- **Contact:**
- **Age:** 16 Yrs.
- **Class:** 10th class completed in this year (2016)
- **School:** Govt. High school, Yeleswaram, Yeleswaram Mandal



MEDICAL HISTORY: Heart Disease, Failure to Thrive

MEDICAL CAMP REPORT (Oct 2014):

- **Doctor** -: Dr. NARAYANA BABU (pediatrician), C/o Sai Sudha Hospital, Kakinada.
- **Complaint:** Chest pain, Failure to Thrive
- **Advised-** Cardiologist Opinion.
- **Diagnosis** –Ventricular Septal Defect (VSD)?

REFERAL DOCTOR REPORT:

- **DOCTOR:** Dr. Srinivas MD .DM Cardiologist, C/o Sai Sudha Hospital, Kakinada.
- **ADVISED:** 2D Echocardiography (TEST) – Congenital Acyanotic Heart Defect, Small Sub Aortic Ventricular Septal Defect.
- **DIAGNOSIS-**Ventricular Septal Defect (VSD)
- **TREATMENT GIVEN:** -> No Surgery needed.

-> Regular follow-ups in case of any surgeries.

-> High Protein Diet.

PRESENT CONDITION: He is Healthy now, and taking healthy diet to improve the general condition of the body. He has been supplied with protein powder for better nutrition levels.



TANA FOUNDATION INDIA (TFI)

PROJECT VAARADHI - MEDICAL REFERRALS (2015-2017)



STUDENT DETAILS:

- **Name:** Salagala Kumari
- **Contact:** 94920 96044
- **Age:** 15 Yrs.
- **Class:** 9th class
- **School :** ZP HS, Kirlampudi, Kirlampudi Mandal



MEDICAL HISTORY: Frequent convulsions (seizures) since childhood.

MEDICAL CAMP REPORT:

- **DOCTOR:** Dr. NARAYANA BABU (pediatrician), C/o Sai Sudha Hospital, Kakinada.
- **COMPLAINT :** Frequent convulsions since childhood.
- **ADVISED:** 1. Liver function test (LFT) -

Electroencephalography (EEG) –Abnormal
Suggestive of ABSENCE SEIZURES.

CT SCAN brain-No Abnormality.

- **DIAGNOSIS:** Absence Seizures.
- **TREATMENT GIVEN:** Tab. Valproate 250 mg BD

PRESENT CONDITION:

- She is doing well now
- Regular Medication of Valproate 250 mg BD for next few years

RECENT FOLLOW-UP:

- **ADVISED:** Liver Function Test (08-12-2016)
- **TREATMENT GIVEN:** Tab. Sodium Valproate 500 (300+200) Mg (Long Term Medication)



TANA FOUNDATION INDIA (TFI)

PROJECT VAARADHI - MEDICAL REFERRALS (2015-2017)



STUDENT DETAILS:

- **Name:** G.Surendhra Raju
- **Contact:** 99481 46928
- **Age:** 14 Yrs.
- **Class:** 8th class
- **School :** ZP HS, Raparthy, Pithapuram Mandal



MEDICAL HISTORY: Frequent convulsions (seizures) since childhood.

MEDICAL CAMP REPORT:

- **DOCTOR:** -: Dr. NAGARAJU (pediatrician), C/o Mother and Child Hospital, Pithapuram
- **COMPLAINT:** Frequent convulsions since childhood
- **ADVISED:** on Seeing Old reports Advised long term medication.
- **DIAGNOSIS:** Generalized Tonic Clonic Convulsions (GTCS)
- **TREATMENT GIVEN:** Tab. Sodium Valproate 250 Mg OD (Long Term Medication)

PRESENT CONDITION:

- He is doing well now
- Regular Medication of Valproate 250 mg BD for next few years

RECENT FOLLOW-UP:

- **DOCTOR :** Dr. NARAYANA BABU (pediatrician), C/o Sai Sudha Hospital, Kakinada.
- **ADVISED:** MRI Scanning (08-11-2016)
- **TREATMENT GIVEN:** Tab. Sodium Valproate 300 Mg OD (Long Term Medication)



TANA FOUNDATION INDIA (TFI)

PROJECT VAARADHI - MEDICAL REFERRALS (2015-2017)



STUDENT DETAILS:

- **Name:** B.Venkata Srinivas
- **Contact :** 90007 92846
- **Age:** 15 Yrs.
- **Class:** 10th class completed in this year (2016)
- **School :** ZP HS, Burugupudi, Kirlampudi Mandal



MEDICAL HISTORY: Heart Disease

MEDICAL CAMP REPORT:

- **DOCTOR:** A. Ravi (pediatrician), C/o Sai Sudha Hospital, Kakinada.
- **COMPLAINT:** Chest pain, Failure to Thrive.
- **ADVISED:** Cardiologist Opinion.
- **DIAGNOSIS- TREATMENT GIVEN:** SURGERY-Atrial septal Defect Repair (ASD repair)

REFERAL DOCTOR REPORT:

- **DOCTOR:** C/o Surya Global Hospital, Madhavapatnam, Kakinada.
- **COMPLAINT:** Breathlessness, Failure to Thrive.
- **DIAGNOSIS:** Congenital Heart Disease- **Atrial Septal Defect (ASD)**
- **TREATMENT GIVEN:** Congenital Heart Disease- **Atrial Septal Defect (ASD)**

PRESENT CONDITION: He is Healthy now, and taking healthy diet to improve the general condition of the body



TANA FOUNDATION INDIA (TFI)

PROJECT VAARADHI - MEDICAL REFERRALS (2015-2017)



STUDENT DETAILS:

- **Name:** V. Vajra Kumari
- **Contact:** 97052 56984
- **Age:** 16Yrs.
- **Class:** 9th class
- **School :** ZP HS Veeravaram, Kirlampudi Mandal



MEDICAL HISTORY: Past Fracture of Right Leg

MEDICAL CAMP REPORT:

- **DOCTOR :** Dr. NARAYANA BABU (pediatrician), C/o Sai Sudha Hospital, Kakinada.
- **COMPLAINT:** Right Leg Deformity with Limp.
- **ADVISED:** Orthopedic Opinion.
- **DIAGNOSIS:** Mal union of Past Fracture.

FIRST VISIT (Nov 2015)

REFERAL DOCTOR REPORT:

- **DOCTOR:** Dr. Surendra Babu (Orthopedic Surgeon), C/o Sai Sudha Hospital, Kakinada.
- **ADVISED:** X-ray Right Leg- Nonunion of Fracture ends with Deformity.
- **DIAGNOSIS:** - Right Leg Nonunion with Leg Deformity of Past Fracture and Shortening of Limb.
- **TREATMENT GIVEN:** SURGERY – CORRECTION SURGERY AND LIMB LENGTHING PROCEDURE.

Surgery performed successfully on 16-11-2015 at Sai Sudha Hospital, Kakinada. She was on bed rest for almost 6 months. We have informed the school administration as well as the mandal educational officer. They have promised to help the girl with attendance so that she will not have to lose an academic year.



TANA FOUNDATION INDIA (TFI)

PROJECT VAARADHI - MEDICAL REFERRALS (2015-2017)



SECOND VISIT (May 2016)

- **DOCTOR:** Dr.Sivaram (Orthopaedic Surgeon), C/o Sai Sudha Hospital, Kakinada.
- **ADMITTED FOR:** Post-operative Tibia plating right with exposed implant with pus discharge.
- **DIAGNOSIS:** - Tibia plating right with exposed implant with pus discharge.
- **TREATMENT GIVEN:** Surgery (03-05-2016)-DCP FROM TIBIA REMOVED AND WOUND DEBRIDMENT.

THIRD VISIT (May 2016)

- **DOCTOR:** Dr.T.Mohan Rao (Plastic Surgeon), C/o Sai Sudha Hospital, Kakinada.
- **DIAGNOSIS:** POST TRAUMATIC DEFECT LEFT LEG EXPOSING TIBIA.
- **TREATMENT GIVEN:** Surgery (11-05-2016)-Flap cover for trauma of the leg with exposure of the underlying vital structures like tendons, nerves, vessels, bone with or without any fracture-flap insert.

PRESENT CONDITION:

She is Healthy now and under constant medication. She is also being provided with protein powder packets to improve her nutritional levels.



TANA FOUNDATION INDIA (TFI)

PROJECT VAARADHI - MEDICAL REFERRALS (2015-2017)



STUDENT DETAILS:

- **Name:** CH.Lakshmi Durga Ganesh
- **Contact:** 99593 75560
- **Age:** 15 Yrs.
- **Class:** 8th class
- **School :** ZPHS Chandramamampalli, Peddapuram Mandal



MEDICAL HISTORY: Walking on Toes, Surgery done in past, showed some improvement, But after few years same problem reoccurred.

MEDICAL CAMP REPORT:

- **DOCTOR:** Dr. Nagaraju (pediatrician), C/o Mother and Child Hospital, Pithapuram..
- **COMPLAINT:** walking on toes, weakness of limbs
- **ADVISED:** Orthopedic Opinion.
- **DIAGNOSIS:** Mal union of Past Fracture.

REFERAL DOCTOR REPORT:

- **DOCTOR:** Dr. Surendra Babu (Orthopaedic Surgeon), C/o Sai Sudha Hospital, Kakinada.
- **ADVISED:** Muscle Biopsy (NIMS, Hyderabad)
- **DIAGNOSIS:** Severe Bilateral Tendoachillis contracture with Equinus Foot Deformity
- **TREATMENT GIVEN:** SURGERY

PRESENT CONDITION:

Waiting for Muscle Biopsy (NIMS, Hyderabad)



TANA FOUNDATION INDIA (TFI)

PROJECT VAARADHI - MEDICAL REFERRALS (2015-2017)



STUDENT DETAILS:

- **Name:** G.Bhanusri
- **Contact:** 96528 99591
- **Age:** 12 Yrs.
- **Class:** 7th class
- **School :** ZPHS Pamarru, K.Gangavaram Mandal



MEDICAL HISTORY: Fracture of left humerus

DOCTOR REPORT (Nov 2015):

- **DOCTOR:** Dr. Nalamati Purusothama Rao and Dr.Syam Sundar (Orthopaedic Surgeon), C/o Safe Hospital, Kakinada.
- **COMPLAINT:** Collar bone fracture
- **ADVISED:** Surgery correction of long bone fracture
- **DIAGNOSIS** Fracture of left humerus
- **TREATMENT GIVEN:** K-wire fixation

PRESENT CONDITION:

Surgery performed successfully on 25-11-2015 at Safe Hospital, Kakinada. She was on bed rest for 3-4 months. We have informed the school administration as well as the mandal educational officer. They have promised to help the girl with attendance so that she will not have to lose an academic year.

She has now recovered fully and back to school.



TANA FOUNDATION INDIA (TFI)

PROJECT VAARADHI - MEDICAL REFERRALS (2015-2017)



STUDENT DETAILS:

- **Name:** N. Durga Rao
- **Contact:** 94905 13852
- **Age:** 11 Yrs.
- **Class:** 8th class
- **School :** Yeleswaram Government High School, Yeleswaram Mandal .



MEDICAL HISTORY:

MEDICAL CAMP REPORT (Dec 2015)

- **DOCTOR:** Dr. Avinash Mahindrakar ,C/o Kiran Eye Hospital, Kakinada
- **COMPLAINT:** Defective vision in both eyes by birth
- **ADVISED:** Yag capsulotomy in right eye and lens aspiration + IOL under GA in left eye
- **DIAGNOSIS:** pseudoplakia with PCO in right eye and congenital cataract in left eye.

PRESENT CONDITION:

BCV in right eye was 20/200 and in left eye was 20/100.

He was diagnosed to have Nystagmus with Pseudoplakia in both eyes with Exotropia in right eye.

He was advised glasses and patch for 2hrs/day in left eye and review for **squint** evaluation after 6 months.

He will be taken to the doctor again for follow up for squint evaluation.



TANA FOUNDATION INDIA (TFI)

PROJECT VAARADHI - MEDICAL REFERRALS (2015-2017)



STUDENT DETAILS:

- **Name:** Chand Basha
- **Contact:** 84980 71693, 96408 95355
- **Age:** 15 Yrs.
- **Class:** 10th class
- **School :**Recharla peta High School, Kakinada Urban Mandal .



MEDICAL HISTORY:

- **DOCTOR:** -: Dr. NARAYANA BABU (pediatrician), C/o Sai Sudha Hospital, Kakinada
- **COMPLAINT:** Physically Handicapped.
- **TREATMENT:** Recently he has been provide with Jaipur Foot.

PRESENT CONDITION: He is Healthy now, and taking healthy diet



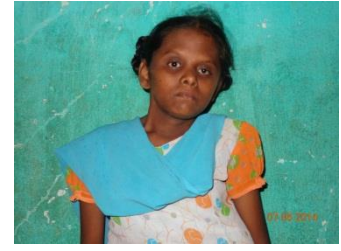TANA FOUNDATION INDIA (TFI)

PROJECT VAARADHI - MEDICAL REFERRALS (2015-2017)



STUDENT DETAILS:

- **Name:** U.Satyavathi
- **Contact:** 78939 59477
- **Age:** 15 Yrs.
- **Class:** 9th class
- **School:** Tamarada High School, Kirlampudi Mandal.



MEDICAL HISTORY:

- **DOCTOR:** -: Dr. NARAYANA BABU (pediatrician), C/o Sai Sudha Hospital, Kakinada
- **COMPLAINT:** Physically Handicapped and Ophthalmology Opinion.
- **TREATMENT :** She was provided with Eye Glasses & also a brand new Tricycle for her to move around easily.

PRESENT CONDITION: She is Healthy now, and taking healthy diet



TANA FOUNDATION INDIA (TFI)

PROJECT VAARADHI - MEDICAL REFERRALS (2015-2017)



STUDENT DETAILS:

- **Name:** M.Rani
- **Contact:** 78934 89593
- **Age:** 15 Yrs.
- **Class:** 9th class
- **School :** Geddanapalli High School, Kirlampudi Mandal .



MEDICAL HISTORY:

- **DOCTOR:** -: Dr. NARAYANA BABU (pediatrician), C/o Sai Sudha Hospital, Kakinada
- **COMPLAINT:** Thyroid Problem.
- **TREATMENT :** Long term Medication

PRESENT CONDITION: She is Healthy now, and taking healthy diet.



TANA FOUNDATION INDIA (TFI)

PROJECT VAARADHI - MEDICAL REFERRALS (2015-2017)



STUDENT DETAILS:

- **Name:** P.Keerthi
- **Contact:** 88978 17151
- **Age:** 12 Yrs.
- **Class:** 7th class
- **School :** Lingamparthy High School, Yeleswaram Mandal .



MEDICAL HISTORY:

Leg Bone fracture.

- **DOCTOR:** -: Dr. Rajanikath, Yeleswaram
- **COMPLAINT:** Broken Leg.
- **TREATMENT :** Broken Leg was treated and provided the required medication

PRESENT CONDITION: She is back to normal and attending school.



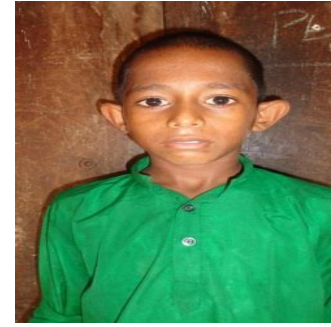TANA FOUNDATION INDIA (TFI)

PROJECT VAARADHI - MEDICAL REFERRALS (2015-2017)



STUDENT DETAILS:

- **Name:** K.Ganesh
- **Contact:** 77022 45210
- **Age:** 13 Yrs.
- **Class:** 7th class
- **School :** Rajiv Gandhi Municipal High School, Pithapuram Mandal.



MEDICAL HISTORY:

- **DOCTOR:** -: Dr. Sivaram (Orthopaedic Surgeon), C/o Sai Sudha Hospital, Kakinada
- **ADMITTED FOR:** Implant removal from right forearm.
- **DIAGNOSIS:** Post OP radius plating from right side fracture united.
- **TREATMENT OFFERED:** Surgical (06-05-2016)
- **SURGERY:** Plate removed from right radius. Under strict aseptic precautions G.A given. Patient kept in supine position Draping done. Incision given along the previous surgical scar over right radius on volar aspect. Plate exposed screws and plate removed. Hemostasis secured. Wound closed with layers.

PRESENT CONDITION: He is Healthy now, and taking healthy diet.



TANA FOUNDATION INDIA (TFI)

PROJECT VAARADHI - MEDICAL REFERRALS (2015-2017)



STUDENT DETAILS:

- **Name:** M.Veera Durga
- **Contact:** 90638 86247
- **Age:** 12 Yrs.
- **Class:** 7th class
- **School :** Lingamparthy High School, Yeleswaram Mandal.



MEDICAL HISTORY:

- **DOCTOR:** -: Dr. Avinash Mahindrakar, C/o Kiran Eye Hospital, Kakinada
- **DIAGNOSIS:** Eye Problem (Both Eyes).
- **TREATMENT OFFERED:** Glasses Given (15-09-2016), MRI Scan for Brain has done

PRESENT CONDITION: She is Healthy now, and taking healthy diet.



TANA FOUNDATION INDIA (TFI)

PROJECT VAARADHI - MEDICAL REFERRALS (2015-2017)



STUDENT DETAILS:

- **Name:** S.Lova Raju
- **Contact:** 94903 29804
- **Age:** 12 Yrs.
- **Class:** 7th class
- **School :** Yeleswaram Govt. High School, Yeleswaram Mandal.



MEDICAL HISTORY:

- **DOCTOR:** -: Dr. M.Ravi Kumar Raju (ENT), C/o Hope Hospital, Kakinada
- **DIAGNOSIS:** Ear Problem.
- **TREATMENT OFFERED:** Medicine (Ear drops & Tablets) given. Surgery recommended after 3 years.
- **SURGERY:**

PRESENT CONDITION: He is Healthy now, and taking healthy diet.



TANA FOUNDATION INDIA (TFI)

PROJECT VAARADHI - MEDICAL REFERRALS (2015-2017)



STUDENT DETAILS:

- **Name:** K.Divya Teja
- **Contact:** 95504 48320
- **Age:** 13 Yrs.
- **Class:** 8th class
- **School :** Yeleswaram Girls High School, Yeleswaram Mandal.



MEDICAL HISTORY:

- **DOCTOR:** -: Dr. M.Ravi Kumar Raju (ENT), C/o Hope Hospital,Kakinada
- **ADMITTED FOR:** Surgery for tonsillitis.
- **DIAGNOSIS:** tonsillitis and Ear problem.

- **TREATMENT OFFERED:** Surgery recommended for tonsillitis.
- **SURGERY:** Done (19-10-2016).

PRESENT CONDITION: She is Healthy now, and taking healthy diet.

RECENT FOLLOW-UP:

- **DOCTOR:** -: Dr. Bhima Shankhar (Pulmonology), C/o Hope Hospital,Kakinada
- **ADVISED:** Chest X-Ray (14-12-2016)
- **TREATMENT GIVEN:** Medicine Given for Severe cough with blood.

RECENT FOLLOW-UP:

- **DOCTOR:** -: Dr. Bhima Shankhar (Pulmonology), C/o Hope Hospital,Kakinada
- **ADVISED:** CT-Scan (28-12-2016)
- **TREATMENT GIVEN:** Medicine Given for Severe cough with blood.

STUDENT DETAILS:

- **Name:** K.Venkata Ramana
- **Contat:** 97043 47924
- **Age:** 12 Yrs.
- **Class:** 7th class
- **School :** Kovvada High School, Kakinada(R) Mandal.



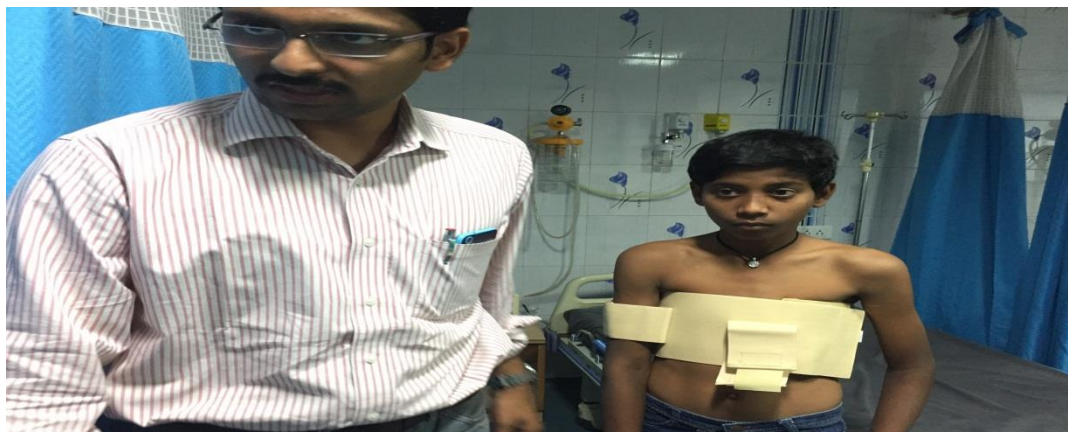MEDICAL HISTORY:

- **DOCTOR:** -: Dr. Siva Kumar (Orthopaedic Surgeon), C/o Sai Sudha Hospital, Kakinada
- **DIAGNOSIS:** Bone Fracture at right hand.
- **ADVISED:** X-Ray for Shoulder.
- **TREATMENT OFFERED:** Belt provided (27-12-2016) for hand. Medicine Given.

PRESENT CONDITION: He is Healthy now, and taking healthy diet.

RECENT FOLLOW-UP:

- **DOCTOR:** -: Dr. Siva Kumar (Orthopaedic Surgeon), C/o Sai Sudha Hospital, Kakinada
- **ADVISED:** X-Ray for Shoulder Joint, AP-Lateral (19-01-2017).
- **TREATMENT OFFERED:** Medicine Given.






TANA FOUNDATION INDIA (TFI)

PROJECT VAARADHI - MEDICAL REFERRALS (2015-2017)



STUDENT DETAILS:

- **Name:** K.V.V.Satyanarayana
- **Contat:** 99898 00854
- **Age:** 15 Yrs.
- **Class:** 10th class
- **School :** Pamarru High School, K.Gangavaram Mandal.



MEDICAL HISTORY:

- **DOCTOR:** -: Dr.P.Naresh Kumar,M.S.(GEN),C/o BEST Hospital, Kakinada
- **DIAGNOSIS:** Acute Appendicitis.
- **ADVISED:** Surgery for Appendix

- **TREATMENT OFFERED:** Surgery Done (18-02-2017) at BEST Hospital, Kakinada. Medicines Given.

PRESENT CONDITION: He is Healthy now, and taking healthy diet.